

## 1.6 Head injuries

### Quick guide

First aid. Vital diagnosis: unconscious? → breathing? → pulse?	Protection against new accident Keep the patient alive: CPR if needed Haemorrhage compression Notify EMS (112) Avoid further complications (protection, cervical immobilisation, safety position, safety transfer) Assess Glasgow levels. Hospital transfer - with ICU - Neurosurgery?
First remedy for head injuries	<b>Arnica</b>
Consequences of head trauma: vertigo, absences, blindness, coma, concussion, convulsions, headache, dullness, madness, sadness, suicidal thoughts, and memory loss	<b>Natrium sulphuricum</b>
Violent convulsions with spasms arching the spine, with catalepsy and screaming; headache, dullness, sadness, memory loss, mental and developmental retardation, and post-traumatic vertigo	<b>Cicuta</b>
Stupor and coma due to injury, shock or stroke; face flushed, hot, jaw dropping, hot perspiration; apnoea, hoarse breathing; narcolepsy, sleep	<b>Opium</b>

## 1. Traumatism

Dullness and stupefaction, slow to answer, weak memory, passive, apathetic, indifferent, blank; meningism, with automatic chewing movements, brain cry, frowning	<b>Helleborus</b>
Mental and emotional symptoms after injury: depression, dullness, forgetfulness, hysteria; seizures due to head and spine injuries, with tetanic rigidity, tonic, starting from the spine	<b>Hypericum</b>
Diffuse axonal injury, cerebral contusion and intra-parenchymal haemorrhage with seizures, coma, automatic chewing movements, gnashing, gasping for breath; carpal spasms	<b>Cuprum</b>
Clonic convulsions, epileptic-type, with opisthotonos and paralysis due to head injuries; headache, numbness, memory loss, grief and post-traumatic vertigo; great restlessness, moving neck, body, and legs continuously, < at night; muscle tension; < cold, > heat	<b>Rhus toxicodendron</b>
Convulsions and meningism from head injury, with delirium and headache; violent symptoms and behaviour, with facial flushing and cold extremities: compare with <i>Stramonium</i> , <i>Hyoscyamus</i>	<b>Belladonna</b>
When pain predominates in the occipital area with great heaviness of the eyelids, weakness, poor muscle strength, and trembling limbs	<b>Gelsemium</b>

## Introduction

Head injuries are becoming more frequent and severe, mainly due to traffic, work, and sports related accidents. We will thoroughly approach them with a section on the repertory's symptoms to facilitate the choice of the best remedy or combination of remedies, alongside a specific materia medica and clinical cases to help us understand the usefulness of homeopathic remedies as adjuvant to necessary conventional measures.

## Diagnosis

You can **suspect a cranial fracture** by the following signs:

- External visible wound and obvious deformity
- Bleeding from the ears, nose, or both
- Seepage of cerebrospinal fluid by ears, nose, or the wound itself
- Bruising around the eyes (periorbital)
- Pupils of different size (anisocoria)
- Very **likely brain damage** when the patient presents with:
- Radical change of personality / confusion, disorientation / slurred speech or hearing
- Impaired balance
- Impaired breathing, irregular pauses or apnoeas (Cheyne Stokes); heart rhythm disturbances

## First aid

### 1. Objectives

- a. Protection against a new accident. Urgent and very quick measures to protect the injured and the rescuers against falling rocks, buildings, impact of other vehicles, fire or water.
- b. Keep the patient alive, with the brain well perfused and oxygenated until they reach the hospital and, if required, the neurosurgeon.
- c. Prevent bleeding.
- d. Avoid injuries and complications.
- e. Give notice to the Emergency Medical Services as quickly as possible.

## 1. Traumatism

---

### 2. Assess pulse and respiration

- a. Keep the airway open. Check ventilation. Be prepared for intubation and assisted ventilation if breathing stops.
- b. Complete resuscitation if necessary (CPR).

### 3. Control bleeding. If bleeding is visible:

- a. Apply sterile dressing with pressure.
- b. Install venous perfusion and monitor blood pressure.

### 4. Avoid complications

- a. New neurological damage
  - i. Do not move the patient before applying **cervical immobilisation**, this will be done very carefully (cervical collar). Head injuries are often accompanied with cervical and spine lesions.

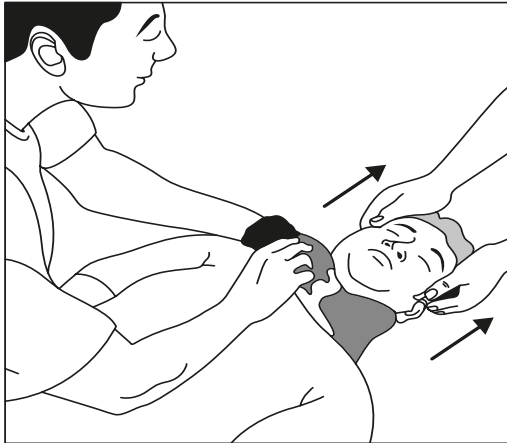
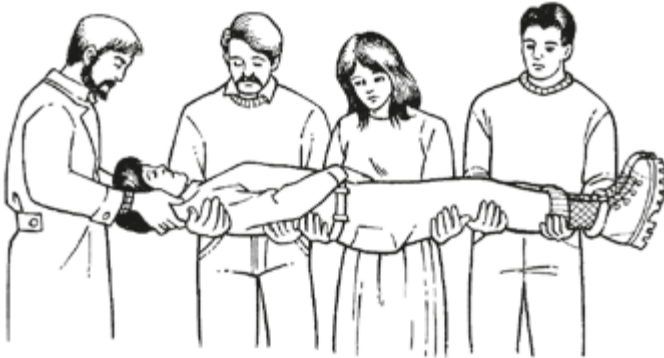

Fig. 1.6.1

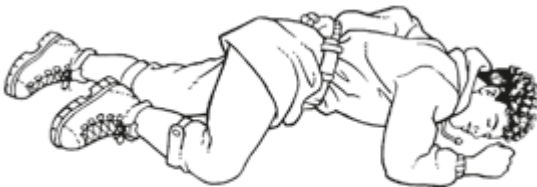- ii. Transfer to the stretcher for transportation to the hospital with the safety transfer (minimum 4 people)



Safety transfer in case of spinal lesions

Fig. 1.6.2

- b. Aspiration of vomit: if the person vomits once the cervical area is immobilised, rotate the patient slightly to the side (semi-prone), in recovery position, if you can rule out spinal injury. This rotation should be made very carefully, slowly, following safety transfer procedures.



Injured person in recovery position

Fig. 1.6.3

- c. Infection: treat open wounds with **sterile**, simple application without trying to inspect the wound. In absence of gauze, use clothes or towels. In extreme cases, the rescuer's hand can be lifesaving.
5. **Transfer to hospital. Assess state of consciousness.** Note the state of consciousness for clinical information. In blunt trauma, although the patient is conscious, monitor the risk of post-traumatic cerebral haemorrhage.

## 1. Traumatisms

---

- a. **Glasgow Method:** eye (4) + verbal (5) + motor (6)
- b. **Simplified method** of 4 grades: alert / verbal only / only pain / unconscious.
- c. **Arnica 30C** sublingual immediately and repeated often (every 10-20 min). If the patient is unconscious, administer diluted medication, a few sublingual drops with a syringe. If a higher potency is available, 1M or 10M, it is preferable in these circumstances to use them. Arnica is the first homeopathic remedy to administer and the most useful during the first minutes/hours of the accident.

Let's see the importance of rapid response in the case of a gunshot wound to the head, in the multiple murder which sent shock waves worldwide, in Tucson (Arizona), and which seriously wounded U.S. Congresswoman Gabrielle Giffords, in January 2011. The congresswoman, who was presumed dead at first, was rescued by her Hispanic assistant, Daniel Hernandez. His account is as follows:

*“As I approached, there were several wounded people lying on the floor. The first thing I tried to do was find out who was alive. I started checking to see if they breathed and if they had a pulse. I checked two or three people who were dead before I realised that they had shot the congresswoman. I saw she was wounded in the head and because of the severity of the wound, she became my priority. There was a lot of bleeding and, in her position, there was a risk she would choke on her own blood. I sat her up. I put her on my chest to breathe. Then, I applied pressure on the wound. What could I use? I had no more than my hand until someone went into a store and brought shirts. “One reason for the survival of the congresswoman was the quick arrival to the hospital. In less than forty minutes, she was in the operating room.” (Peirón, 2011)*

### **Comatose patient, hospitalised**

The patient with head injury and coma will be treated in an intensive care unit in a hospital with a neurosurgery department. Follow established protocols. Homeopathic treatment has proven effective in resolving some serious head trauma. The hospital may have specialists in homeopathy who could help in treating these patients.